

Dual intraocular lens implantation: Monofocal lens in the bag and additional diffractive multifocal lens in the sulcus

Georg Gerten, MD, Omid Kermani, MD, Karl Schmiedt, MD, Elham Farvili, MD, Andreas Foerster, MD, Uwe Oberheide, PhD

PURPOSE: To evaluate a new diffractive multifocal intraocular lens (IOL) as an additional (add-on) IOL for sulcus-based implantation.

SETTING: Augenklinik am Neumarkt, Köln, Germany.

METHODS: In this prospective study, cataract patients had phacoemulsification and IOL implantation. After phacoemulsification, an aspheric silicone monofocal IOL (MS 612 ASP-Y) with a power range of +4.00 to +27.00 diopters [D] was implanted in the capsular bag. This was followed by sulcus placement of an add-on multifocal IOL (MS 714 PB) with a +3.50 D diffractive element for near but zero refractive power for distance.

RESULTS: The study included 56 eyes of 30 patients. Three months postoperatively, the mean monocular uncorrected distance visual acuity was 0.10 logMAR \pm 0.11 (SD) (median 1.00 decimal; 20/20 Snellen), with a remaining mean postoperative spherical equivalent of 0.01 \pm 0.51 D. The mean uncorrected intermediate visual acuity was 0.20 \pm 0.15 logMAR (median 0.63 decimal; 20/30 Snellen) with a luminance of 500 lux at 1 m. The mean uncorrected near visual acuity (Early Treatment Diabetic Retinopathy chart) was 0.16 \pm 0.13 logMAR (median 0.80 decimal; Jaeger 2). No major complications (eg, iris chafing, iris capture, lens epithelial cell ingrowth, glaucoma) were associated with the add-on IOL in the sulcus.

CONCLUSIONS: Combined implantation of an add-on diffractive sulcus IOL and a monofocal capsular bag IOL was safe and effective in improving far and near visual acuity in cataract surgery. Preliminary visual acuity results were similar to those in eyes with a single 1-piece diffractive multifocal IOL.

J Cataract Refract Surg 2009; 35:2136–2143 © 2009 ASCRS and ESCRS

Monofocal intraocular lenses (IOLs) provide adequate restoration of visual acuity in pseudophakic eyes, although often with spectacle dependence, especially for near tasks.^{1,2} With growing interest in presbyopia correction,^{3,4} several surgical methods were developed to provide near visual acuity without spectacles in presbyopic phakic eyes^{5,6} and pseudophakic eyes.^{2,7–10}

Several new IOL optic designs have been proposed for pseudophakic eyes. One of the most clinically successful concepts is the simultaneous projection of a far image and a near image on the retina.¹⁰ Because the first generation of bifocal IOLs relied on the refractive principle, their performance was very dependent on pupil size and, compared with monofocal IOLs, they had potential adverse optical effects, such as loss of contrast sensitivity and compromised visual acuity

under various lighting conditions.¹¹ A new generation of diffractive multifocal IOLs was developed to resolve the issue of spectacle dependency by providing balanced distance and near visual acuity while being less dependent on pupil size.¹² However, studies^{2,7–12} show that even the latest generation of multifocal IOLs can cause a loss of contrast sensitivity, an increase in spherical aberrations, and halo and glare symptoms. Thus, many patients elect not to have multifocal IOL implantation because they fear developing night-vision problems. Explantation of a diffractive IOL and its replacement by a monofocal IOL is a possible, although not desirable, solution. The concept of an additional functional diffractive optic is an alternative for uneventful reversibility of this complex refractive surgical procedure.

There is a growing demand for spectacle independence by pseudophakic patients with monofocal IOLs. Again, an option is to replace the monofocal IOL with a multifocal IOL; however, IOL explantation followed by multifocal IOL implantation can be traumatic,¹³ especially if the posterior capsule has been opened. Also, after IOL exchange, perfect IOL centration is hard to achieve and precise refractive outcomes are difficult to predict. A technique to avoid the risks of explanting and replacing an existing IOL is to implant an additional (add-on) multifocal IOL in the sulcus, with the goal of enhancing the patient's vision. Intraocular lens explantation is not suitable in many cases, especially if the existing posterior chamber IOL (PC IOL) successfully corrects cylindrical ametropia in the pseudophakic eye, as occurs with toric IOLs.¹⁴ If patients have a residual refractive error after cataract surgery, an add-on IOL can be customized with additional refractive properties. Patients with unilateral pseudophakia and a monofocal IOL who require cataract surgery in the second eye can be offered the option of diffractive multifocal IOL implantation in the capsular bag in the second eye and an add-on diffractive multifocal IOL in the pseudophakic eye.

In this study, we evaluated the safety and efficacy of improving near visual acuity of combined implantation of a monofocal IOL in the capsular bag and a new diffractive multifocal intraocular lens (IOL) as an add-on lens in the sulcus.

PATIENTS AND METHODS

This prospective randomized clinical study included cataract patients who had a preoperative corrected distance visual acuity (CDVA) of logMAR 0.3 (0.5 decimal) or worse. As required by German law, an ethical committee approved the study. All patients provided informed consent according to the Declaration of Helsinki.

Patients were excluded if they had a disease other than cataract that might interfere with multifocal or sulcus-based IOL implantation (eg, age-related macular degeneration, uveitis, glaucoma), corneal abnormalities, or corneal

astigmatism greater than 1.00 diopter (D). After uneventful phacoemulsification, patients had implantation of a monofocal IOL in the capsular bag and a multifocal IOL in the sulcus.

Intraocular Lenses

The monofocal IOL used in the study was the MS 612 ASP-Y (HumanOptics AG). It is a posterior chamber 3-piece foldable IOL with a 360-degree sharp optic edge. The optic is third-generation silicone elastomer with an ultraviolet (UV) inhibitor and yellow tint for blue-light filtering. The yellow tint absorbs blue light to prevent the adverse effects of UV light on the retina while preserving contrast sensitivity and color discrimination.¹⁶ The anterior surface of the optic is spherical. The posterior IOL surface is aspheric, compensating for a mean corneal asphericity of -0.281 with an average curvature of 7.71 mm.¹⁷ The modified C-loop haptics have zero-degree angulation and are high molecular poly(methyl methacrylate) (PMMA) for adequate stability. In this study, the power of the monofocal IOLs was between 4.00 D and 27.00 D.

The multifocal IOL used in the study was the MS 714 PB (HumanOptics AG). It is a diffractive 3-piece foldable add-on IOL designed for implantation in the sulcus. The 7.0 mm optic and 14.0 mm haptics are sized to prevent glare effects and iris capture, provide stability, and prevent contact with the PC IOL. The silicone elastomer optic is safe and secure,¹⁸ with a UV absorber, a concave posterior surface, and round anterior edge to prevent iris irritation. The haptics, which are angulated 10 degrees from the iris, are high-molecular PMMA with a modified C-loop configuration. The IOL power varies from -6.00 to $+6.00$ D in 0.50 D increments; it can be customized with additional lens power. In this study, IOLs with 0.00 D power were used. The diffractive element is similar to that of other commercially available intracapsular diffractive IOLs. From the inner diameter of 1.2 mm to the outer diameter of 3.6 mm, 9 steps on the anterior IOL surface create an interference pattern at a specific focal length to generate a near focus. The diffractive element of the IOL is equivalent to a near addition of $+3.50$ D at the IOL plane, which provides near focus at approximately 40 cm. Approximately 18% of incoming light is lost by the process of diffraction in higher-order maxima. The remaining 82% of incoming light is usable for the visual process and is distributed on the 2 focal planes for near and far. With a small pupil (approximately 2.0 mm), the light distribution between far focus and near focus is approximately 50/50; as the pupil enlarges, the ratio slowly increases to 70/30 with a 5.0 mm pupil.

Preoperative Examination

All patients had a complete preoperative ophthalmic examination including subjective and objective refractions, biomicroscopy of the anterior segment, intraocular pressure (IOP) measurement, endothelial cell count (ECC), and optical biometry (IOLMaster, Carl Zeiss Meditec). The Haigis formula¹⁵ was used for IOL calculation. Patients also had Scheimpflug imaging of the anterior segment (Pentacam, Oculus) and dilated fundus examination.

Surgical Technique

Standard sutureless microincision phacoemulsification was performed by the same surgeon (G.G.). Paralytic or topical anesthesia of preservative-free lidocaine 2% and

Submitted: March 6, 2009.

Final revision submitted: July 6, 2009.

Accepted: July 9, 2009.

From Augenklinik am Neumarkt, Köln, Germany.

No author has a financial or proprietary interest in any material or method mentioned.

Presented in part at the XXVI Congress of the European Society of Cataract & Refractive Surgeons, Berlin, Germany, September 2008.

Corresponding author: Georg Gerten, MD, Augenklinik am Neumarkt, Schildergasse 107-109, 50667, Köln, Germany. E-mail: g.gerten@augenportal.de.

mild sedation with midazolam were administered. Sufficient pupil dilation was achieved with intracameral mydriasis using 1 mL of a 2 mL vial containing cyclopentolate 1%, phenylephrine 10%, lignocaine 2%, and a balanced salt solution. An astigmatism-neutral incision (2.6 mm × 1.5 mm) was placed temporally. An S3 phaco unit (Geuder AG) with a piranha phaco tip was used for surgery (80% ultrasound power, bimanual phaco-chop technique).

After phacoemulsification, the monofocal IOL was implanted in the capsular bag. The sodium hyaluronate 1% (Provisc) was removed from behind the capsular bag IOL and the sulcus opened with additional ophthalmic viscosurgical device (OVD). The diffractive add-on IOL was loaded in a cartridge and inserted into an injector (Abbott Medical Optics, Inc.). The tip of the cartridge was introduced partially into the eye, and the leading haptic of the add-on IOL was slowly released into the sulcus. The proximal haptic was placed in the sulcus with a second instrument (push-pull manipulator, Geuder AG) while the add-on IOL was slowly rotated. After the OVD was bimanually removed anteriorly and from between the IOLs, the incisions were hydrated with a 30-gauge cannula. Intraocular preservative-free cefuroxime 1% (0.1 cc) was injected into the anterior chamber. No sutures were used in any case. Postoperative topical therapy comprised ofloxacin and prednisolone 1% eyedrops 5 times a day.

Postoperative Examination

All patients had a complete postoperative ophthalmic examination, including monocular and binocular CDVA, uncorrected distance visual acuity (UDVA), uncorrected intermediate visual acuity, corrected intermediate visual acuity, uncorrected near visual acuity (UNVA), and corrected near visual acuity (CNVA). Intermediate visual acuity was measured with Early Treatment Diabetic Retinopathy (EDTRS) charts (Precision Vision) at 1 m with a luminance of 500 lux controlled by a lux meter (Voltcraft MS-1500, Conrad Electronic SE). Near visual acuity was also measured with EDTRS charts with a luminance of 1000 to 1100 lux at 40 cm. Visual acuity was measured in decimal units and converted to logMAR units for statistical analysis.

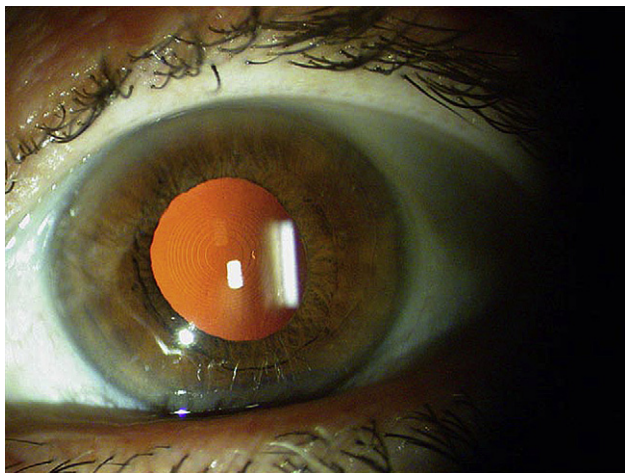


Figure 1. A PC IOL and an add-on IOL in the sulcus the first day after implantation.

The postoperative examination included biomicroscopy of the anterior segment and IOP measurement at 1 day, 1 week, and 1 and 3 months. At the 3-month visit, patients also had measurement of corrected and uncorrected visual acuity at all 3 distances, an ECC, Scheimpflug anterior segment imaging, and a dilated fundus examination. Intraocular lens centration was evaluated during the slitlamp examination, with the ring-shaped steps of the diffractive element used as landmarks. As in all Fresnel optics, the rings on the add-on surface are concentric but not equidistant. The diameter of the inner ring is 1.2 mm, and the diameter of the next outer ring is approximately 1.6 mm. Most elderly patients have small pupils that, under bright slitlamp illumination, are no larger than 2.0 to 2.5 mm. If the pupil were 2.4 mm and the complete inner ring structure of the add-on were visible, decentration could be estimated to be 0.5 mm or less. If the 2 inner ring structures were visible, decentration would be 0.3 mm or less. The add-on IOL was considered centered if the inner ring structure was completely visible.

RESULTS

This study included 56 eyes of 30 patients (15 men, 15 women). The mean age of the patients was 65 years ± 12 (SD).

All monofocal IOLs and add-on multifocal IOLs were implanted successfully (Figure 1). All add-on IOLs were well centered throughout the postoperative follow-up (Figure 2).

Table 1 shows the monocular and binocular uncorrected and corrected near, intermediate, and distance visual acuities. Figure 3 compares the preoperative and postoperative monocular CDVA. Figure 4 shows the uncorrected and corrected visual acuity results at all 3 distances at 3 months. All eyes achieved a UNVA of at least 0.5 decimal, which was sufficient for reading newspaper-size print without spectacles.

Figure 5 shows the anterior chamber depth (ACD) results. No eye had shallowing of the anterior chamber.

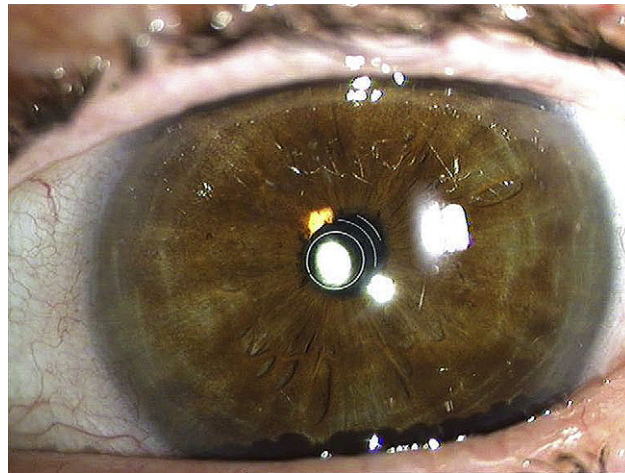


Figure 2. Well-centered add-on IOL in a miotic eye.

Table 1. Three-month visual acuity results.

Distance/Parameter	Visual Acuity			
	Uncorrected		Corrected*	
	Monocular	Binocular	Monocular	Binocular
Near				
Mean (logMAR) ± SD	0.16 ± 0.13	0.08 ± 0.08	0.12 ± 0.14	0.05 ± 0.08
Range (decimal)	0.32 to 1.00	0.50 to 1.00	0.25 to 1.00	0.40 to 1.00
Median (decimal)	0.80	0.80	0.80	1.00
Interquartile range	0.63 to 0.80	0.80 to 1.00	0.63 to 1.00	0.80 to 1.00
Intermediate				
Mean (logMAR)	0.20 ± 0.15	0.11 ± 0.12	0.17 ± 0.12	0.09 ± 0.09
Range (decimal)	0.20 to 1.00	0.32 to 1.25	0.32 to 1.00	0.50 to 1.00
Median (decimal)	0.63	0.80	0.63	0.80
Interquartile range	0.50 to 0.80	0.63 to 1.00	0.63 to 0.80	0.80 to 1.00
Distance				
Mean (logMAR) ± SD	0.10 ± 0.11	0.02 ± 0.07	0.02 ± 0.06	-0.02 ± 0.05
Range (decimal)	0.4 to 1.25	0.63 to 1.25	0.63 to 1.25	0.80 to 1.25
Median (decimal)	0.80	1.00	1.00	1.00
Interquartile range	0.80 to 1.00	0.80 to 1.00	0.80 to 1.00	1.00 to 1.00

*Spectacle correction

Figure 6 shows the predictability results. The mean targeted spherical equivalent (SE) was 0.09 ± 0.25 D and the mean achieved SE, 0.01 ± 0.51 D, showing good predictability.

No complications, such as lens epithelial cell (LEC) growth, were associated with the distance between the 2 IOLs (Figure 7). The mean distance between the back surface of the add-on IOL and the anterior surface of the monofocal IOL was 450 ± 190 μm (Figure 8).

Centration of the add-on IOL (assessed at the slitlamp) was stable at 3 months. In all but 1 eye (ectopic pupil), the inner ring structure of the add-on was completely visible with a 2.0 to 3.0 mm pupil under the bright light of the slitlamp (Figure 2). Based on the diameter of the Fresnel optic ring structures on

the surface of the add-on IOL, decentration was to be 0.5 or less in 55 eyes (98.2%).

Table 2 shows the postoperative complications. The presence of the sulcus add-on IOL was not associated with any complication (ie, loss of iris pigment, prolonged irritation of the anterior chamber, shallow anterior chamber, glaucoma, LEC proliferation between IOLs, iris capture). Intraocular lens pigment deposits were seen on some add-on IOLs during the first postoperative month; they resolved by the third postoperative month. In 1 eye with extreme intraoperative mydriasis, 1 of the 2 haptics of the add-on IOL was inadvertently implanted in the anterior chamber. This error, which was likely related to the learning curve for implanting this new IOL, was recognized

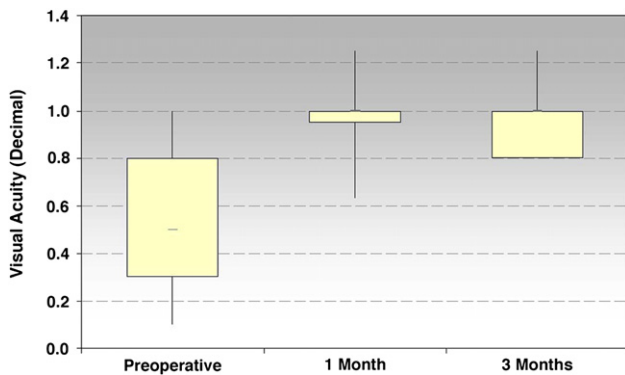


Figure 3. Preoperative and postoperative monocular CDVA.

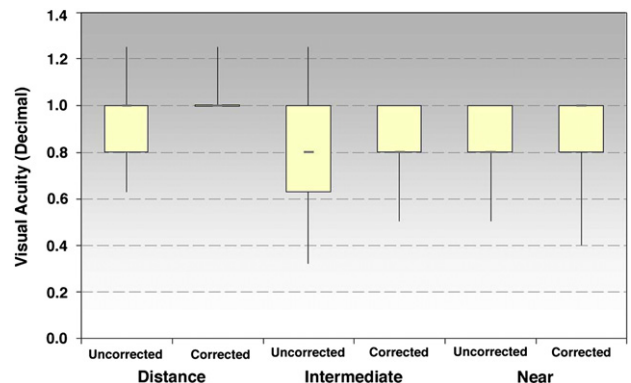


Figure 4. Uncorrected and corrected visual acuity at all distances 3 months postoperatively.

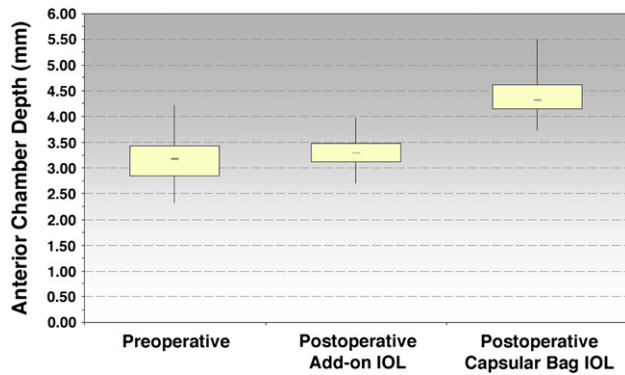


Figure 5. Comparison of preoperative and postoperative ACD (IOL = intraocular lens).

at the first postoperative visit and corrected by rotating the misplaced haptic into the sulcus. In 2 eyes, 1 haptic of the add-on IOL was bent or cracked during implantation. In the case with the cracked haptic, the add-on IOL was explanted and replaced during the same surgery. In the case with the bent haptic, the add-on IOL was left in place and the PMMA haptics recovered, which recentered the IOL. In another case with a slightly ectopic pupil, the add-on IOL was not perfectly matched with the line of sight (decentration approximately 0.8 mm). However, the decentration did not affect the clinical result and the IOL was left in the eye. The rate of posterior capsule opacification (PCO) with subsequent neodymium:YAG (Nd:YAG) capsulotomy was approximately 28%.

No patient required spectacles for distance vision. Two patients required spectacles for near tasks 3 months after implantation.

DISCUSSION

Add-on diffractive multifocal IOLs designed for implantation in the sulcus appear to produce visual




Figure 7. Scheimpflug image of the distance between the monofocal IOL in the bag and the multifocal IOL in the sulcus.

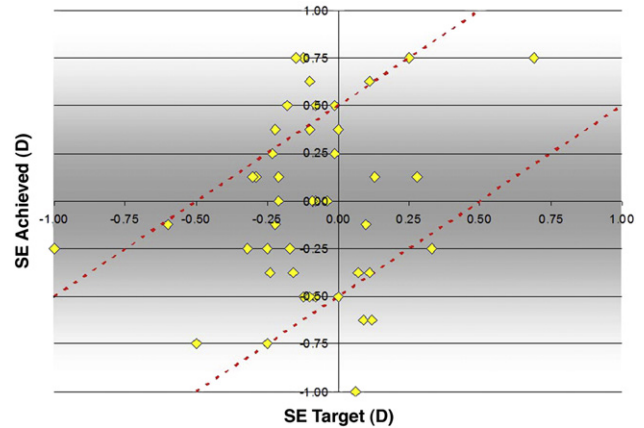


Figure 6. Targeted SE versus achieved SE (predictability) (SE = spherical equivalent).

results that are as good as, and in some cases better than, those of single diffractive multifocal IOLs.^{12,19} In a study of an apodized diffractive multifocal IOL, de Vries et al.²⁰ found a mean UDVA of 0.046 ± 0.099 logMAR and a mean CDVA of -0.040 ± 0.075 logMAR at 6 months. The mean UNVA and CNVA were the same, 0.009 ± 0.029 logMAR. In a study of another diffractive multifocal IOL,²¹ 90.0% of eyes achieved a monocular UDVA of 20/30 or better and 92.8% of patients were spectacle independent 6 months after surgery. In our study, the addition of an optical interface in a pseudophakic eye caused no serious problems, making it a safe and effective procedure. There was no LEC ingrowth because the proper distance was maintained between the IOLs.²² There were no cases of anterior chamber shallowing, and no eye required iridectomy as of the last follow-up. A larger study to verify these findings is required.

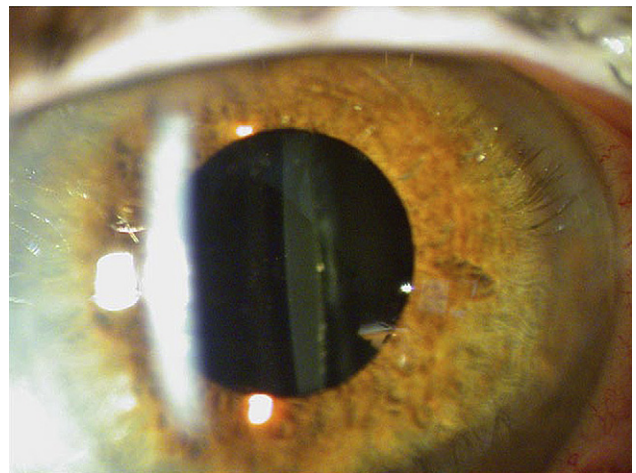


Figure 8. A photograph taken at 1 week shows sufficient distance between the anterior add-on IOL and the PC IOL at all sites.

Table 2. Complications.

Complication	Eyes (n)
Pupil deformation	2
Pigment deposits*	4
Cell deposits (macrophages)*	3
False add-on haptic implantation	1
Relative add-on IOL decentration [†]	1

IOL = intraocular lens

*One week postoperatively, resolved by 3-month visit

[†]Asymptomatic

The exclusion criteria for sulcus implantation of an add-on diffractive multifocal IOL mirrors those for implantation of a conventional multifocal IOL. In addition, a single add-on multifocal IOL can be used in patients with problems such as light scatter or aberrations, slight amblyopia, mild epiretinal gliosis, tear-film deficiency, unusual refractions, or uncertain patient expectations. If the IOL does not satisfy the patient, it can be removed easily at almost any time postoperatively.

Taking into account the preoperative refractive distribution and the dioptric range of the IOL, the refractive results in our study were excellent. All patients were informed about the possibility that the add-on IOL might have to be exchanged or that they might have to have laser in situ keratomileusis as a second intervention. Intermediate uncorrected visual acuity results showed reasonable outcomes that are similar to those reported for other multifocal IOLs.^{12,20,21}

Posterior capsule opacification is the most common complication of modern cataract surgery, with an incidence of up to 50% at 2 years.²³ In our study, the PCO with Nd:YAG rate was relatively high compared with that after monofocal IOL implantation. However, reports of the PCO and Nd:YAG rates in eyes with multifocal IOLs are conflicting.^{20,24,25} It has been speculated that multifocal IOL distribution of light to 2 foci stresses the visual system to the limit. If additional optical disturbances (eg, defocus, astigmatism, aberration, straylight) occur, the visual system may be overstressed. If patients with a multifocal or add-on IOL tend to be more sensitive to scatter or straylight, even low levels of PCO can lead to subjective complaints and subsequent Nd:YAG laser capsulotomy. This theory is supported by our clinical observation. Although we did not assess PCO objectively, some of our patients, even those with relatively low-grade PCO, reported subjective visual symptoms, despite good high-contrast visual acuity; the symptoms resolved after Nd:YAG laser capsulotomy. Neodymium:YAG laser posterior capsulotomy significantly improves

stereoacuity, more so than it improves spatial acuity and contrast sensitivity.²⁶ Stereoacuity and contrast sensitivity are essential to the proper functioning of diffractive multifocal IOLs, which further supports the benefit of early Nd:YAG treatment in eyes with a multifocal or add-on IOL. This issue must be further evaluated in future studies.

With regard to method and technique, diffractive multifocal IOLs are easy to implant in the sulcus with a forceps or an injector or shooter system. An injector system for the add-on multifocal IOL we used is under development (A. Messner, CEO, HumanOptics AG, personal communication, January 2009). It is important to enlarge the sulcus with OVD to avoid in-the-bag or anterior chamber placement of the leading haptic. The haptics of the add-on IOL diffractive are very flexible and have good shape memory. In addition, the optic is large enough to prevent iris capture and to allow the use of mydriatics without problems. So far, no adjustments of biometric constants have been necessary in the implantation procedure; however, a study with a larger cohort is needed to further assess this.

Although implantation of a new-generation diffractive multifocal IOL alone offers an alternative to bilateral and unilateral pseudophakic patients, the decrease in contrast sensitivity and the incidence of halos and glare can compromise optical performance. The reduction in contrast sensitivity might be caused by the IOL's principle of dividing and directing incoming light between 2 focal points.²⁷ A greater incidence of photopic phenomena has been reported with multifocal IOLs than with monofocal IOLs.¹ However, patients can often adapt to these symptoms, and it is for the patient to decide whether the benefits outweigh the disadvantages. If there is concern that a patient will not be able to adapt to the side effects of the diffractive optic, an add-on multifocal IOL in the sulcus can be easily explanted. If the capsular bag were not suitable for a diffractive IOL (eg, because of zonule rupture, broken posterior capsule, inadequate capsulorhexis leading to unpredictable bag shrinkage), it would not preclude implantation of an IOL in the sulcus.

Sulcus placement is a possible reason that the add-on IOLs in our study were well centered 3 months postoperatively. Sulcus IOLs are not subject to capsular bag abnormalities, deformation, or shrinkage. In our study, centration was assessed by the position of ring structure of the Fresnel optic on the IOL surface in relation to the pupil margin. Other methods of evaluating IOL centration included Scheimpflug photography,^{28,29} digital slitlamp photographs,³⁰ and Purkinje reflections.³¹ Because of different study designs (eg, different reference points and methods), results are conflicting and not directly comparable to

those in our study. Our method of evaluating add-on IOL centration is not a precise measurement but is an easy way to obtain a reasonably exact estimation of centration for clinical purposes. Future studies should be performed to determine the best way to measure centration of this IOL in a clinical setting.

The full dioptric range is not yet available for some capsular bag diffractive multifocal IOLs. Again, combined implantation of a monofocal IOL in the capsular bag and an add-on multifocal IOL in the sulcus can provide a solution. Combined sulcus implantation of an add-on IOL with other IOL types—for example a toric IOL in the capsular bag—can also be considered (personal experience).


The concept of piggyback IOLs (ie, implanting 2 IOLs in the capsular bag) has been proposed.^{32–36} However, the results are unpredictable because of optical disturbances (contact zones with Newton rings),³⁵ LEC ingrowth between the IOLs (interlenticular opacity),³⁶ and capsular bag shrinkage that leads to IOL displacement.³ However, implanting 1 IOL in the capsular bag and a second in the sulcus produces better results.³⁷ Intraocular lenses placed in the sulcus that are not designed for sulcus fixation are not shaped to prevent contact with the capsular bag IOL, which can lead to unstable fixation, iris irritation, and chronic intraocular inflammation.^{38–40} The posterior concave optic of the diffractive multifocal add-on IOL we used prevents contact with the capsular bag IOL because the rounded optic edge and the design of the optical zone do not cause iris irritation. The larger optic (7.0 mm) prevents undesired glare effects and iris capture, and the 14.0 mm total diameter provides stable centration in the ciliary sulcus.

In conclusion, implantation of an add-on diffractive multifocal IOL in the sulcus in cataract surgery patients was safe, predictable, and efficient and further improved visual results. However, subjective evaluation must be performed to validate the stability of contrast sensitivity and the incidence of halos and glare. In addition, sulcus-placed add-on diffractive multifocal IOLs should be evaluated with different posterior chamber IOLs (eg, toric and aspheric) and IOLs of different materials. Add-on IOLs have the potential to correct small residual refractive errors in pseudophakic eyes with a monofocal IOL while also providing near vision. This raises the question of whether add-on IOLs can be used as secondary IOLs in different pseudophakic eyes. A study to address this issue is underway.

REFERENCES

- Martínez Palmer A, Gómez Faiña P, España Albelda A, Comas Serrano M, Saad DN, Castilla Céspedes M. Visual function with bilateral implantation of monofocal and multifocal intraocular lenses: a prospective, randomized, controlled clinical trial. *J Refract Surg* 2008; 24:257–264
- Leyland M, Zinicola E. Multifocal versus monofocal intraocular lenses in cataract surgery; a systematic review. *Ophthalmology* 2003; 110:1789–1798
- Helmholtz H. Ueber die Accomodation des Auges. *Albrecht von Graefes Arch Ophthalmol* 1855; 1(2):1–74
- Glasser A. Restoration of accommodation. *Curr Opin Ophthalmol* 2006; 17:12–18
- Gerten G, Ripken T, Breitenfeld P, Krueger RR, Kerami O, Lubatschowski H, Oberheide U. In-vitro- und In-vivo-Untersuchungen zur Presbyopiebehandlung mit Femtosekundenlasern. [In vitro and in vivo investigations on the treatment of presbyopia using femtosecond lasers]. *Ophthalmologe* 2007; 104:40–46
- Schumacher S, Fromm M, Oberheide U, Gerten G, Wegener A, Lubatschowski H. In vivo application and imaging of intralenticular femtosecond laser pulses for the restoration of accommodation. *J Refract Surg* 2008; 24:991–995
- Steinert RF, Aker BL, Trentacost DJ, Smith PJ, Tarantino N. A prospective comparative study of the AMO ARRAY zonal progressive multifocal silicone intraocular lens and a monofocal intraocular lens. *Ophthalmology* 1999; 106:1243–1255
- Leyland MD, Langan L, Goolfee F, Lee N, Bloom PA. Prospective randomised double-masked trial of bilateral multifocal, bifocal or monofocal intraocular lenses. *Eye* 2002; 16:481–490
- Javitt JC, Steinert RF. Cataract extraction with multifocal intraocular lens implantation; a multinational clinical trial evaluating clinical, functional, and quality-of-life outcomes. *Ophthalmology* 2000; 107:2040–2048
- Ortiz D, Alió JL, Bernabéu G, Pongo V. Optical performance of monofocal and multifocal intraocular lenses in the human eye. *J Cataract Refract Surg* 2008; 34:755–762
- Kim CY, Chung S-H, Kim T-I, Cho YJ, Yoon G, Seo KY. Comparison of higher-order aberration and contrast sensitivity in monofocal and multifocal intraocular lenses. *Yonsei Med J* 2007; 48:627–633. Available at <http://www.pubmedcentral.nih.gov/picrender.fcgi?artid=2628042&blobtype=pdf>. Accessed August 27, 2009
- Cillino S, Casuccio A, Di Pace F, Morreale R, Pillitteri F, Cillino G, Lodato G. One-year outcomes with new-generation multifocal intraocular lenses. *Ophthalmology* 2008; 115:1508–1516
- Joffe L, Smiddy WE, Flynn HW Jr. Posterior segment complications. In: Fishkind WJ, ed, *Complications in Phacoemulsification; Avoidance, Recognition, and Management*. New York, NY, Thieme, 2002; 204–222
- Gerten G, Michels A, Olmes A. Torische Intraokularlinsen; klinische Ergebnisse und Rotationsstabilität. [Toric intraocular lenses; clinical results and rotational stability]. *Ophthalmologe* 2001; 98:715–720
- Haigis W, Lege B, Miller N, Schneider B. Comparison of immersion ultrasound biometry and partial coherence interferometry for intraocular lens calculation according to Haigis. *Graefes Arch Clin Exp Ophthalmol* 2000; 238:765–773
- Rodríguez-Galíetero A, Montés-Micó R, Muñoz G, Albarrán-Diego C. Comparison of contrast sensitivity and color discrimination after clear and yellow intraocular lens implantation. *J Cataract Refract Surg* 2005; 31:1736–1740
- Beiko GHH, Haigis W, Steinmueller A. Distribution of corneal spherical aberration in a comprehensive ophthalmology practice and whether keratometry can predict aberration values. *J Cataract Refract Surg* 2007; 33:848–858
- Legeais J-M. Materials for intraocular lenses. In: Garg A, Fry LL, Tabin G, Gutiérrez-Carmona FJ, Pandey SK, eds, *Clinical Practice in Small Incision Cataract Surgery; Phaco Manual*. New Delhi, India, Jaypee Brothers, 2004; 320–343

19. Alió JL, Elkady B, Ortiz D, Bernabeu G. Clinical outcomes and intraocular optical quality of a diffractive multifocal intraocular lens with asymmetrical light distribution. *J Cataract Refract Surg* 2008; 34:942–948
20. de Vries NE, Webers CAB, Montés-Micó R, Tahzib NG, Cheng YYY, de Brabander J, Hendrikse F, Nuijts RMMA. Long-term follow-up of a multifocal apodized diffractive intraocular lens after cataract surgery. *J Cataract Refract Surg* 2008; 34:1476–1482
21. Goes FJ. Refractive lens exchange with the diffractive multifocal Tecnis ZM900 intraocular lens. *J Refract Surg* 2008; 24:243–250
22. Buratto L, Bellucci R. Cataract surgery and intraocular lens implantation in severe hyperopia. In: Buratto L, Osher RH, Masket S, eds. *Cataract Surgery in Complicated Cases*. Thorofare, NJ, Slack, 2000; 73–85
23. Slagsvold JE. 3 M diffractive multifocal intraocular lens: eight year follow-up. *J Cataract Refract Surg* 2000; 26:402–407
24. Apple DJ, Solomon KD, Tetz MR, Assia EI, Holland EY, Legler UFC, Tsai JC, Castaneda VE, Hoggatt JP, Kostick AMP. Posterior capsule opacification. *Surv Ophthalmol* 1992; 37:73–116
25. Wormstone IM, Wang L, Liu CSC. Posterior capsule opacification. *Exp Eye Res* 2009; 88:257–269
26. Menon GJ, Wong KK, Bundhun T, Ewings P, Twomey JM. The effect of Nd:YAG laser posterior capsulotomy on stereoacuity. *Eye* 2009; 23:186–189
27. Montés-Micó R, Alió JL. Distance and near contrast sensitivity function after multifocal intraocular lens implantation. *J Cataract Refract Surg* 2003; 29:703–711
28. Hayashi K, Hayashi H, Nakao F, Hayashi F. Correlation between pupillary size and intraocular lens decentration and visual acuity of a zonal-progressive multifocal lens and a monofocal lens. *Ophthalmology* 2001; 108:2011–2017
29. Lee D-H, Shin S-C, Joo C-K. Effect of a capsular tension ring on intraocular lens decentration and tilting after cataract surgery. *J Cataract Refract Surg* 2002; 28:843–846
30. Becker KA, Holzer MP, Reuland AJ, Auffarth GU. Genauigkeit der Linsenstärkenberechnung und Zentrierung einer asphärischen Intraokularlinse. [Accuracy of lens power calculation and centration of an aspheric intraocular lens]. *Ophthalmologie* 2006; 103:873–876
31. Mutlu FM, Erdurman C, Sobaci G, Bayraktar MZ. Comparison of tilt and decentration of 1-piece and 3-piece hydrophobic acrylic intraocular lenses. *J Cataract Refract Surg* 2005; 31:343–347
32. Alfonso JF, Fernández-Vega L, Baamonde MB. Secondary diffractive bifocal piggyback intraocular lens implantation. *J Cataract Refract Surg* 2006; 32:1938–1943
33. Mittelviefhaus H. Piggyback intraocular lens with exchangeable optic. *J Cataract Refract Surg* 1996; 22:676–681
34. Moustafa B, Häberle H, Wirbelauer C, Pham DT. Refraktive Langzeitergebnisse nach Huckepackimplantation. [Refractive long-term results after piggyback intraocular lens implantation]. *Ophthalmologie* 2007; 104:790–794
35. Findl O, Menapace R, Georgopoulos M, Kiss B, Petternel V, Rainer G. Morphological appearance and size of contact zones of piggyback intraocular lenses. *J Cataract Refract Surg* 2001; 27:219–223
36. Werner L, Mamalis N, Stevens S, Hunter B, Chew JLL, Vargas LG. Interlenticular opacification: dual-optic versus piggyback intraocular lenses. *J Cataract Refract Surg* 2006; 32:655–661
37. Baumeister M, Kohlen T. Scheimpflug measurement of intraocular lens position after piggyback implantation of foldable intraocular lenses in eyes with high hyperopia. *J Cataract Refract Surg* 2006; 32:2098–2104
38. Bayramlar H, Hepsen IF, Yilmaz H. Myopic shift from the predicted refraction after sulcus fixation of PMMA posterior chamber intraocular lenses. *Can J Ophthalmol* 2006; 41:78–82. Available at <http://article.pubs.nrc-cnrc.gc.ca/RPAS/rpv?hm=Hlnit&calyLang=eng&journal=cjo&volume=41&afpf=i05103.pdf>. Accessed August 18, 2009
39. Suto C, Hori S, Fukuyama E, Akura J. Adjusting intraocular lens power for sulcus fixation. *J Cataract Refract Surg* 2003; 29:1913–1917
40. LeBoyer RM, Werner L, Snyder ME, Mamalis N, Riemann CD, Augsberger JJ. Acute haptic-induced ciliary sulcus irritation associated with single-piece AcrySof intraocular lenses. *J Cataract Refract Surg* 2005; 31:1421–1427



First author:
Georg Gerten, MD
*Augenlinik am Neumarkt,
Köln, Germany*