

Retrospective study of retinal detachment following neodymium:YAG laser posterior capsulotomy

Michael-Ulrich Dardenne, M.D., Georg-Johannes Gerten, M.D., Kyros Kokkas, M.D., Omid Kermani, M.D.

ABSTRACT

A retrospective study of 1,000 cases that had Nd:YAG laser posterior capsulotomy after cataract surgery is presented. We analyzed the correlation of the patient's age, axial length of the eye, method of cataract surgery, and laser parameters (exposures, energy, and burst mode) with the incidence of retinal detachment (1.6% overall). The highest risk for retinal detachment (12.3%) was in patients with an axial eye length of 26.1 mm to 28.0 mm. The average age of patients with retinal detachments was 60.6 years, ten years younger than the collective average age. Laser parameters, such as energy, exposures, and burst mode, and the method of cataract surgery (extracapsular or phacoemulsification) did not correlate with the incidence of retinal detachment. After surgical treatment of the 16 retinal detachments, a good postoperative visual acuity (better than 20/40) was achieved in most cases.

Key Words: neodymium:YAG laser, posterior capsulotomy, retinal detachment

With the increase of extracapsular cataract extraction (ECCE) and phacoemulsification, secondary posterior capsule opacification has become a frequent occurrence. Retaining an intact posterior capsule reduces the incidence of retinal detachment.¹⁻⁴ After secondary surgical discission there is a significant increase in the retinal detachment incidence.^{3,4}

Since the early 1980s, the Nd:YAG laser has provided a noninvasive alternative for posterior capsulotomy. With the widespread use of the laser, numerous authors have reported the complications of this treatment.⁵⁻¹⁰

Special interest has been directed toward the postoperative transitory intraocular pressure (IOP) rise, a frequent complication that can be controlled in most cases.^{11,12,13} Other studies reported more severe complications, such as retinal detachment, occurring after

Nd:YAG laser capsulotomy.^{14,15,16} The incidence of retinal detachment after Nd:YAG laser capsulotomy seems to be lower than the incidence after surgical discission of the posterior capsule.⁴ In a retrospective study, we looked for the risk factors predisposing to retinal detachment after Nd:YAG laser treatment in 1,000 cases.

MATERIALS AND METHODS

We investigated 1,000 Nd:YAG laser posterior capsulotomies, performed in the Department of Microsurgery of the Eye (University Hospitals Bonn, West Germany) from January 1, 1984, to May 15, 1988. The patients had a follow-up of one to four years (2.4 years average). The majority of patients had received uncomplicated cataract surgery in our clinic. Phacoemulsification was performed in 81.7% of the

From the Department of Microsurgery of the Eye, University Hospitals Bonn, Bonn, West Germany.

Reprint requests to Prof. Dr. Dr. h. c. M. U. Dardenne, Ulrich-Dardenne-Stiftung-Bonn e. V., Friedrich-Ebertstrasse 27, D-5300 Bonn-Bad Godesberg, West Germany.

cases. The remainder had ECCE (18.3%). A posterior chamber intraocular lens (IOL) was implanted in 87.4% of all eyes.

Before and after the laser treatment, all patients had an ophthalmological examination that included visual acuity, IOP measurement with Goldmann tonometer, and slitlamp examination. Fundus examination was performed through the dilated pupil before and after laser treatment. Biometric ultrasound measurement (A-scan) of the axial eye length was performed for IOL power calculation.

We used a mode-locked Nd:YAG laser (Meditec) emitting picosecond laser pulses of 1,064 nm wavelength (16-degree cone angle). All laser parameters (energy, exposures, and burst mode) were recorded. The diameter of the central capsulotomies did not exceed 3 mm to 4 mm.

Steroid eyedrops were prescribed after laser treatment four times a day for seven days. Patients who had more than 50 laser pulses were treated with carbonic/anhydrase inhibitors.

RESULTS

The overall incidence of retinal detachment was 1.6% in 1,000 eyes that had Nd:YAG laser posterior capsulotomy after uncomplicated cataract surgery. We found that most retinal detachments occurred between four and nine months after the laser treatment (Figure 1). No retinal detachment occurred earlier than one month or later than two years after posterior capsulotomy. The interval to the initial cataract surgery is depicted in Figure 2. Most retinal detachments occurred between two and four years after cataract surgery.

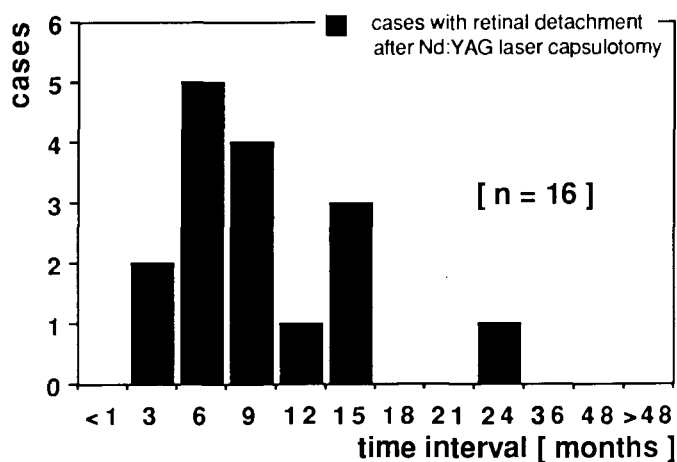


Fig. 1. (Dardenne) The interval between Nd:YAG capsulotomy and occurrence of retinal detachment (n = 16). The maximum time of observation was four years. All retinal detachments occurred within two years of the laser treatment.

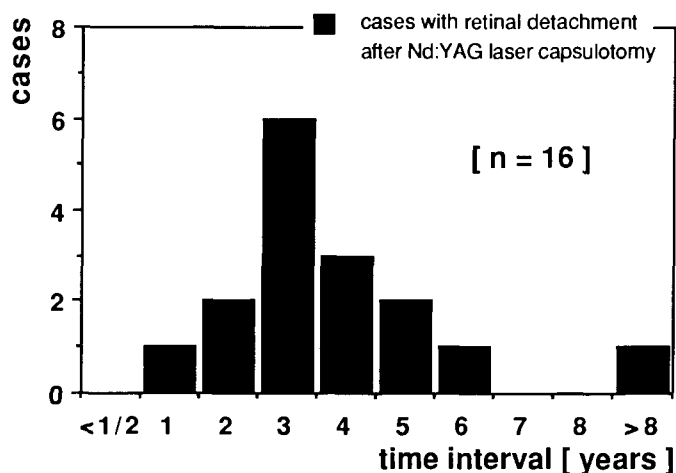


Fig. 2. (Dardenne) The interval between initial cataract surgery and occurrence of retinal detachment (n = 16).

In 12 of the 16 eyes with retinal detachments, retinal holes were found on examinations preceding or during retinal reattachment surgery. Some eyes showed more than one retinal hole. Holes were localized in the superior temporal quadrant in eight eyes and in the superior nasal quadrant in five eyes. Holes were discovered in the lower quadrants in only two eyes.

Eight cases of retinal detachment occurred in the 61 to 70 year old age group (n = 204), leading to an incidence of 3.9% for this age group. Only one patient with a retinal detachment was older than 70 years. The risk for retinal detachment was highest (5.5%) in the 41 to 50 year old age group (n = 55). The average age of the patients with retinal detachment (60.6 years) was significantly lower ($P < .05$) than the average age of those without (70 years). The age distribution of patients with and without retinal detachment is compared (Figure 3).

The axial length of the eye was found to be an important factor in the occurrence of retinal detachment after posterior laser capsulotomy following cataract surgery. Twelve of the affected eyes (75%) had an axial length of more than 25 mm. Eight cases (50%) had an axial length of more than 26 mm (Figure 4). The overall incidence of retinal detachment for eyes with an axial length of more than 25 mm was 5.4%. The incidence of retinal detachment was only 0.5% for those with an axial length of 25 mm or less. No retinal detachment was found in eyes with axial lengths less than 22.1 mm (n = 77) or more than 28.0 mm (n = 34).

No correlation between the surgical technique (81.7% phacoemulsification vs. 18.3% ECCE) and the development of retinal detachment after the Nd:YAG laser treatment was found. The retinal detachment rate was 1.64% in the ECCE group (n = 183) and 1.59% in the phacoemulsification group (n = 817).

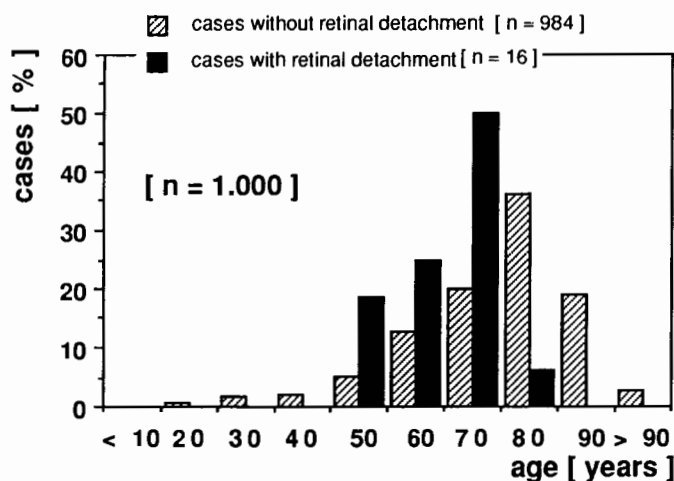


Fig. 3. (Dardenne) The distribution of patients' ages. We compared the cases with (n = 16) and without (n = 984) retinal detachment.

The distribution of the laser pulse energy (1 mJ to 5 mJ), the number of exposures (81 exposures average) and the burst mode (1 to 5) in the cases with retinal detachment was compared to those without retinal detachment (Figure 5). Investigation of the influence of laser parameters such as energy, exposures, and burst mode showed no correlation with the incidence of retinal detachment.

Reattachment surgery was performed on all 16 cases with retinal detachments. In ten cases (62.5%), a final visual acuity of 20/40 or better was achieved postoperatively. In four cases (25.0%), it was 20/25 or better. We compared the visual acuity before the Nd:YAG laser capsulotomy and after the treatment of the retinal detachment. In nine cases (56.3%) there was an overall improvement in visual acuity; in two cases (12.5%) the postoperative visual acuity equaled the level before the Nd:YAG laser capsulotomy; in five cases (31.3%) the visual acuity after the retinal detachment treatment was less than before the Nd:YAG laser treatment. In the latter five cases, the macula was involved in the detachment.

DISCUSSION

In our retrospective study (1,000 cases of Nd:YAG laser posterior capsulotomy), over 50% of the retinal detachment cases (1.6% overall incidence) developed more than six months after the treatment. The results of studies investigating the incidence of retinal detachment after Nd:YAG laser posterior capsulotomy largely depend on the follow-up (Table 1). In studies with a follow-up of six months or less,^{8,9} retinal detachments were considerably fewer than in studies with longer periods of observation.^{4,17} The risk of retinal detach-

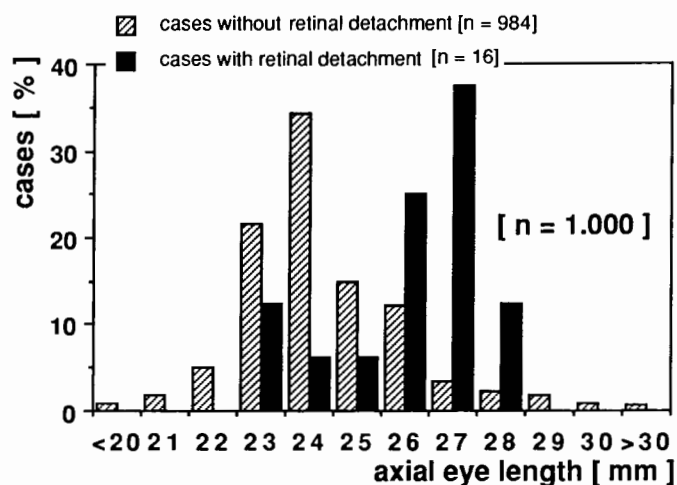


Fig. 4. (Dardenne) The axial lengths of all eyes. We compared the cases with (n = 16) and without (n = 984) retinal detachment.

ment after ECCE or phacoemulsification rises remarkably with a primary surgical capsulotomy to incidences from 2.30%³ to 3.79%.¹⁸ The retinal detachment rates after secondary surgical capsulotomy are even higher (3.2%³ to 6.1%¹⁹). The incidence of retinal detachment after Nd:YAG laser capsulotomy seems considerably lower than the incidence after secondary as well as primary surgical discission. Similar to other studies,^{20,21} our study suggests that patients between

Table 1. The retinal detachment incidence reported by various authors.

Follow-up and Author	Retinal Detachment Incidence
More than six months	
This study	1.60
Knolle ³⁰	2.70
Vester ⁴	1.10
Liesegang ¹⁷	0.98
Johnson ¹²	1.10
Less than or equal to six months	
Johnson ¹²	0.56
Bath ¹⁶	1.20
Stark ⁹	0.50
Keates ⁸	0.40
Unknown	
Terry ¹⁴	2.00
Schneider ²¹	1.80
Winslow ²⁴	0.90
Aron-Rosa ¹⁵	0.08

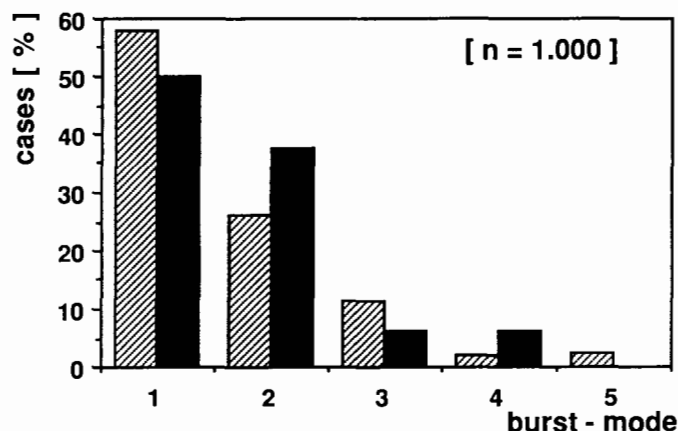
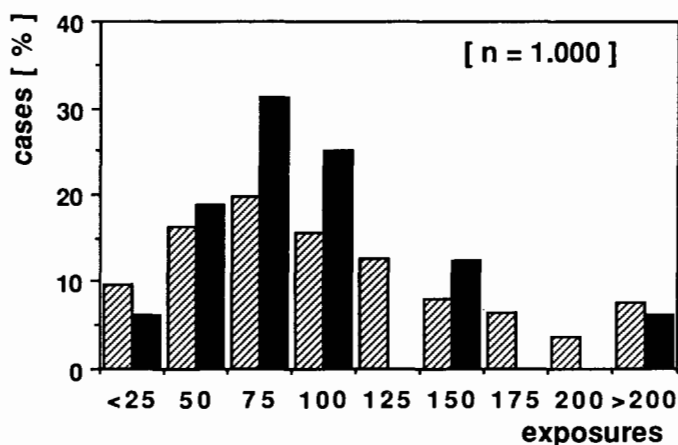
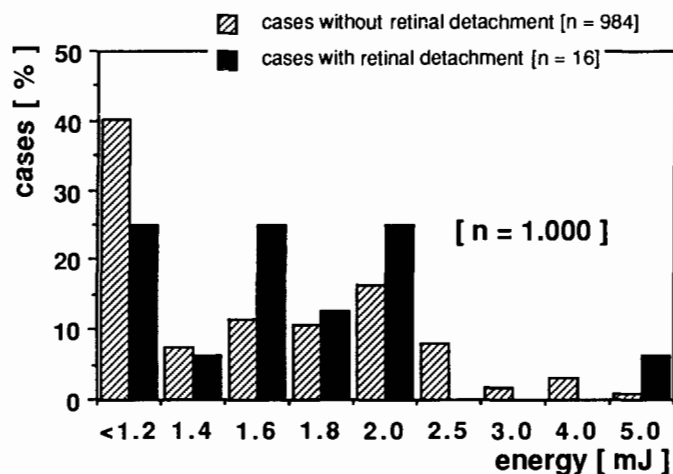


Fig. 5. (Dardenne) The distribution of laser pulse energy (*above left*), number of exposures (*above right*) and burst mode (*left*). We compared the cases with ($n = 16$) and without ($n = 984$) retinal detachment.

40 and 65 years of age are more frequently affected by retinal detachment following Nd:YAG laser posterior capsulotomy. A similar observation has been made for retinal detachment following phacoemulsification, ECCE, and intracapsular cataract extraction.^{2,22,23}

Energy levels, burst mode, and number of exposures did not influence the retinal detachment incidence. Similar results were published by several authors.^{4,24} Other authors reported comparable retinal detachment rates even using higher energy levels.^{12,16} Direct ND:YAG-laser-induced retinal damage is unlikely.^{25,26,27} It seems that the occurrence of retinal detachment is mainly due to the opening of the posterior capsule.²⁴ Maintaining as much capsule as possible prevents vitreous prolapse and assures adequate support for the IOL.^{10,12,28}

Localization of the retinal holes in this study is similar to the one found in a previous study with five cases.²⁰ We did not identify a typical detachment pattern in our series. However, the small number of cases with retinal detachment prevents a reliable statistical evaluation of a detachment pattern.

Myopia is known to be a predisposing factor for the

occurrence of retinal detachment after cataract surgery.²⁹ A coincidence was suggested for myopia and the development of retinal detachment after Nd:YAG laser capsulotomy.^{14,15,17,21} However, no precise data concerning the relation between axial length of the eye and retinal detachment are given in these studies.

CONCLUSION

Analysis of the correlation of patient age, axial length, and laser parameters with the incidence of retinal detachment after 1,000 Nd:YAG laser posterior capsulotomies (1.6% overall incidence) suggests that the highest risk (12.3%) is the myopic patient group with an axial eye length of 26.1 mm to 28.0 mm. We observed a retinal detachment rate of 0.5% in eyes less than 25.1 mm. The average age of the patients with retinal detachments was ten years younger than the collective average age (70 years). The highest incidence (5.5%) was found in patients from 41 to 50 years of age. Laser parameters, such as energy, exposures, and burst mode, and the method of cataract surgery (extracapsular or phacoemulsification) did not correlate with the retinal detachment incidence. The increase in

the incidence of retinal detachment within a relatively short time after capsulotomy supports the thesis of an increasing risk of retinal detachment following the opening of the posterior capsule.

REFERENCES

- Binkhorst CD: Five hundred planned extracapsular extractions with irido-capsular and iris clip lens implantation in senile cataract. *Ophthalmic Surg* 8(3):37-44, 1977
- Jaffe NS, Clayman HM, Jaffe MS: Retinal detachment in myopic eyes after intracapsular and extracapsular cataract extraction. *Am J Ophthalmol* 97:48-52, 1984
- Coonan P, Fung WE, Webster RG Jr, Allen AW Jr, et al: The incidence of retinal detachment following extracapsular cataract extraction: A ten year study. *Ophthalmology* 92:1096-1101, 1985
- Vester CAGM, Bienfait MF, de Jong PTVM, Pameijer JH: Retinal detachment following neodymium-YAG laser capsulotomy. *Fortschr Ophthalmol* 83:441-443, 1986
- Aron-Rosa D, Aron J-J, Greisemann M, Thyzel R: Use of the neodymium-YAG laser to open the posterior capsule after lens implant surgery: A preliminary report. *Am Intra-Ocular Implant Soc J* 6:352-354, 1980
- Fankhauser F, Lörtscher H, van der Zypen E: Clinical studies on high and low power laser radiation upon some structures of the anterior and posterior segments of the eye. *Int Ophthalmol* 5:15-32, 1982
- Katzen LE, Fleischman JA, Trokel SL: The YAG laser: An American experience. *Am Intra-Ocular Implant Soc J* 9: 151-156, 1983
- Keates RH, Steinert RF, Puliafito CA, Maxwell SK: Long-term follow-up of Nd:YAG laser posterior capsulotomy. *Am Intra-Ocular Implant Soc J* 10:164-168, 1984
- Stark WJ, Worthen D, Holladay JT, Murray G: Neodymium: YAG lasers: An FDA report. *Ophthalmology* 92:209-212, 1985
- Dardenne MU, Koch H-R, Klöckner HF: Erste Erfahrungen in der Behandlung von Veränderungen des vorderen Augenabschnitts mit dem Neodymium:YAG-Laser. *Klin Monatsbl Augenheilkd* 186: 87-92, 1985
- Channell MM, Beckman H: Intraocular pressure changes after neodymium-YAG laser posterior capsulotomy. *Arch Ophthalmol* 102:1024-1026, 1984
- Johnson SH, Kratz RP, Olson PF: Clinical experience with the Nd:YAG laser. *Am Intra-Ocular Implant Soc J* 10:452-460, 1984
- Wasserman EL, Axt JC, Sheets JH: Neodymium:YAG laser posterior capsulotomy. *Am Intra-Ocular Implant Soc J* 11: 245-248, 1985
- Terry AC, Stark WJ, Maumenee AE, Fagadau W: Neodymium-YAG laser for posterior capsulotomy. *Am J Ophthalmol* 96: 716-720, 1983
- Aron-Rosa D, Aron J-J, Cohn HC: Use of a pulsed picosecond Nd:YAG laser in 6,664 cases. *Am Intra-Ocular Implant Soc J* 10:35-39, 1984
- Bath PE, Fankhauser F: Long-term results of Nd:YAG laser posterior capsulotomy with the Swiss laser. *J Cataract Refract Surg* 12:150-153, 1986
- Liesegang TJ, Bourne WM, Ilstrup DM: Secondary surgical and neodymium-YAG laser discissions. *Am J Ophthalmol* 100: 510-519, 1985
- Wilkinson CP, Anderson LS, Little JH: Retinal detachment following phacoemulsification. *Ophthalmology* 85:151-156, 1978
- Fung WE, Coonan P, Ho BT: Incidence of retinal detachments following extracapsular cataract extractions; a prospective study. *Retina* 1:232-237, 1981
- Fastenberg DM, Schwartz PL, Lin HZ: Retinal detachment following neodymium-YAG laser capsulotomy. *Am J Ophthalmol* 97:288-291, 1984
- Schneider G: Zur Nachstardisziplin mit dem Nd:YAG-Laser. *Klin Monatsbl Augenheilkd* 187:221-223, 1985
- Ohrloff C, Dardenne MU: Zur Ablationshäufigkeit nach Hinterkammerlinsenimplantation. *Fortschr Ophthalmol* 79: 189-192, 1982
- Wilkinson CP: Pseudophakic retinal detachments. *Retina* 5: 1-4, 1985
- Winslow RL, Taylor BC: Retinal complications following YAG laser capsulotomy. *Ophthalmology* 92:785-789, 1985
- Trokel SL: Optical breakdown and YAG laser physics. In: Trokel SL, ed, *YAG Laser Ophthalmic Microsurgery*. Norwalk, Conn, Appleton-Century-Crofts, 1983, pp 7-14
- Steinert RF, Puliafito CA: Retinal protection. In: Trokel SL, ed, *YAG Laser Ophthalmic Microsurgery*. Norwalk, Conn, Appleton-Century-Crofts, 1983, pp 83-92
- Hiemer H, Hutter H, Gabel VP, Birngruber R: Netzhautschäden bei der Neodymium:YAG-Laserchirurgie im Glaskörperbereich. *Fortschr Ophthalmol* 82:447-449, 1985
- Ruderman JM, Mitchell PG, Kraff M: Pupillary block following Nd:YAG laser capsulotomy. *Ophthalmic Surg* 14:418-419, 1983
- Ashrafzadeh MT, Schepens CL, Elzeneing II, Moura R, et al: Aphakic and phakic retinal detachment. I. Preoperative findings. *Arch Ophthalmol* 89:476-483, 1973
- Knolle GE Jr: Knife versus neodymium:YAG laser posterior capsulotomy: A one-year follow-up. *Am Intraocular Implant Soc J* 11:448-455, 1985